

PREVALENCE OF DISC CUPPING IN NON-GLAUCOMATOUS EYES

JOSÉ PABLO CHIAPPE¹, PABLO NAHUM², JAVIER F. CASIRAGHI², RAFAEL IRIBARREN¹¹Departamento de Oftalmología, Swiss Medical Center Barrio Parque, ²Departamento de Oftalmología, Hospital de Clínicas, Universidad de Buenos Aires, Buenos Aires, Argentina

Abstract This study assessed optic disc size and cupping, using a commercially available ophthalmoscope, in order to show norms of these values for clinical practice. Subjects were office-workers referred from their respective workplaces for a routine medical examination, which included eye examination. The optic disc size was classified as small, medium or large, for having a diameter < 1.0, 1.0-1.5, or > 1.5 times (respectively) the diameter of the ophthalmoscope's selected light spot on the posterior pole. The cupping was classified as the ratio of the vertical cupping diameter and the vertical disc diameter on a relative decimal scale from 0.0 to 1.0. This study included 184 subjects with a mean age of 40.5 ± 9.5 years; 149 (81%) were males. Their mean ocular pressure was 12.4 ± 1.5 mmHg (range 10-17 mmHg). There was a high correlation between optic disc sizes and cupping in the right and left eyes (Pearson Correlation $r = 0.866$, $p < 0.001$); therefore, for simplicity only the data for right eyes are presented. According to our definition, the optic discs in these eyes comprised 27 (14.7%) small, 141 (76.6%) medium and 16 (8.7%) large. The small optic discs were rarely cupped, and the large optic discs were always cupped. Optic disc cupping greater than 0.7 was rarely found and should be suspect of glaucoma. Clinical doctors should be aware of this and refer those subjects with abnormal cupping to the specialist.

Key words: optic disc cupping, disc size

Resumen *Prevalencia de excavación de papila en ojos sin glaucoma.* Este estudio fue concebido para desarrollar normas clínicas sobre el tamaño y la excavación de la papila usando un simple oftalmoscopio en una población emélope sin glaucoma. Los sujetos fueron oficinistas enviados al Centro Médico San Luis para un chequeo general de salud que incluye el examen oftalmológico. El tamaño de la papila o disco óptico fue clasificado en tres diámetros (pequeño, mediano y grande) comparando con el tamaño de la proyección retinal de la luz de un oftalmoscopio de bolsillo. La excavación papilar fue clasificada como la relación entre el diámetro horizontal de la excavación y el diámetro horizontal de la papila en escala decimal de 0.0 a 1.0. El estudio incluye 184 sujetos (edad media de 40.5 ± 9.5 años) y 149 (81%) fueron varones. Su presión ocular promedio fue de 12.4 ± 1.5 mmHg (entre 10-17 mmHg). La correlación tanto de los tamaños de disco óptico como de su excavación, fue alta entre ambos ojos (Correlación de Pearson, $r = 0.866$, $p < 0.001$) de modo que se presentan solamente datos de los ojos derechos. Según nuestra definición de tamaños papilares hubo 27 (14.7%) papilas pequeñas, 141 (76.6%) medianas y 16 (8.7%) grandes. Las papilas pequeñas rara vez tuvieron excavación y las grandes estuvieron siempre excavadas. Fue raro hallar papilas ópticas con una excavación mayor a 0.7, las que deberían hacer sospechar una lesión por glaucoma. Los clínicos avezados en oftalmoscopia deberían tener esto en cuenta para referir los sujetos con excavaciones grandes al especialista para su estudio oftalmológico.

Palabras clave: excavación papilar, tamaño del disco

In 1851 the German physicist, Hermann von Helmholtz, published his monograph titled *Beschreibung eines Auges-Spiegels: zur Untersuchung der Netzhaut im lebenden Auge*, describing in detail the optical principles involved in ophthalmoscopy and the construction of a working device (the first practical ophthalmoscope). From then on, his invention became very useful in the study of the

fundus of the eye, especially for the vascular structures, the macula lutea, and the optic disc. The assessment of optic disc size, while often overlooked, is an important component of the diagnostic evaluation for clinical doctors and ophthalmologists –particularly for the diagnosis of glaucoma, as disc cupping increases with progression of the disease.

Measured values of optic disc size vary with the measurement technique used. At present, we have many different technologies to assess the retina and the optic nerve, but not all of them fit in a pocket and require only a couple of batteries. For the first ocular examination, in the office or at bedside, ophthalmoscopy is a cheap, easy,

Recibido: 24-IV-2014

Aceptado: 21-X-2014

Postal address: Rafael Iribarren, Departamento de Oftalmología, Swiss Medical Center Barrio Parque, San Martín de Tours 2980, 1425 Buenos Aires, Argentina
 Fax: (54-11) 4393-1844 e-mail: rafairibarren@gmail.com

and very useful diagnostic method. In the present study we have used a commercially available ophthalmoscope to assess optic disc size and cupping, in an unselected sample of office workers, in order to show norms of these values for application in clinical practice.

Materials and Methods

This study was conducted in Swiss Medical Center Barrio Parque (San Luis Medical Center). Subjects of both genders, primarily managerial and executive level professionals (working in office tasks), were sent, unselected, by their employers to this clinic for a routine medical exam that comprised general medical, cardiologic, and ophthalmologic evaluation, including a detailed assessment of refractive status. We are not aware of any policy for employment that would prohibit workers with any abnormal conditions related to eye health in this country. Subjects came to the clinic during the morning before work-time. They were instructed to bring their corrective lenses, if they had any, for the eye examination. The tenets of the Declaration of Helsinki were followed. The institution’s review board gave approval for this observational study.

Consecutive subjects, belonging to various different workplaces, were tested during 2010 with the same protocol described in our previous work¹. A single trained ophthalmologist (JPCh) performed all the ophthalmic examinations. All subjects gave their written informed consent for this investigation. Each subject was queried about any history of ocular pathology, such as glaucoma, keratoconus, cataract or strabismus. Unaided distance visual acuity was obtained using an ETDRS optotype card at 3 meters distance (Precision Vision, LaSalle, USA). Only subjects with no ocular pathology and who reached an unaided visual acuity of 20/20 with either eye were considered for this study. These subjects were studied with a Welch-Allyn direct ophthalmoscope (PocketScope, Welch-Allyn, USA), with the light of its smallest spot projected on the retina beside the optic disc. This small spot casts a light spot 1.5 mm in diameter on the retina, over a range of ametropias from + 3.00 to – 5.00 diopters².

The vertical diameter of this spot was compared to the vertical diameter of the optic disc (Fig. 1). Three sizes of optic disc were considered (small, medium and large) according

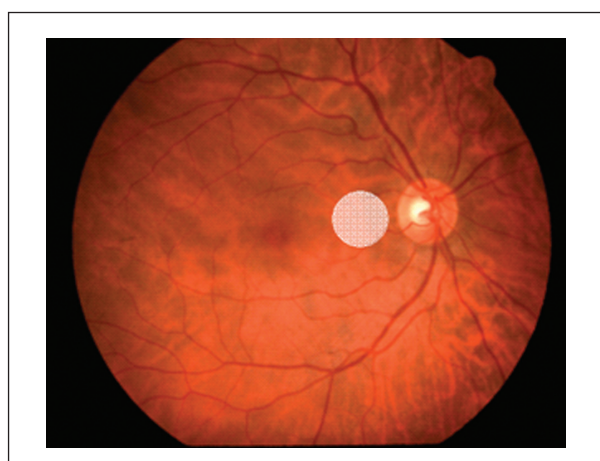


Fig. 1.– Schematic drawing of the ophthalmoscopic light spot projected at the retina beside the optic disc for comparison of both vertical diameters, as described in methods.

to the diameter of this ophthalmoscopic light spot. The disc diameter was classified as “medium” when it was between 1 and 1.5 spot diameters, “small” when it was < 1 spot diameter, and “large” when it was > 1.5 spot diameters. Cupping was quantified with the same ophthalmoscope projecting the light into the optic disc, and the degree of cupping was expressed on a relative decimal scale (0.0 - 1.0)³⁻⁵. Fig. 2 shows schematic cupplings of the Armaly scale. Intra-ocular pressure was measured with a hand-held applanation tonometer (Perkins Mark 2, Clement Clarke International Ltd, Essex, UK).

The relative prevalence of each optic size and amount of cupping are presented as percentages. To test whether the cupping increased with ageing in our subjects, the sample was divided into “younger” and “older” pools, around the median of 40 years, and the means of the amounts of cupping were compared by Mann-Whitney test. Data analyses were performed with statistical software (SPSS version 15.0, SPSS Inc., USA).

Results

This study included 184 subjects, with a mean age of 40.5 ± 9.5 years (range 21 to 75 years); 149 (81%) were

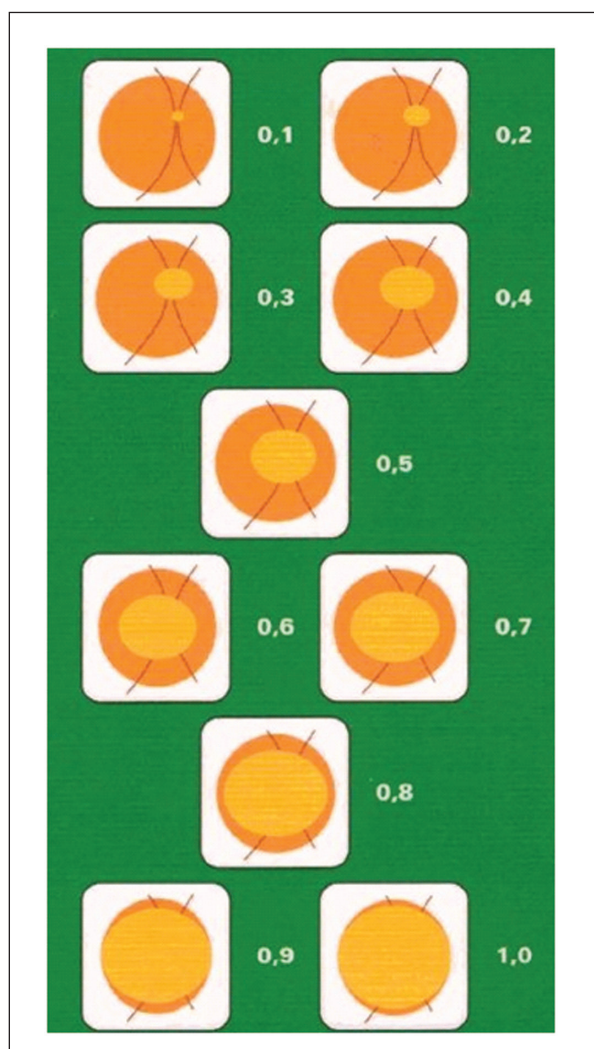


Fig. 2.– Schematic drawings of Armaly decimal scale.

males. Their mean ocular pressure was 12.43 ± 1.49 mmHg (range 10-17 mmHg). There was a high correlation between optic disc sizes and cupping in the right and left eyes (Pearson Correlation $r = 0.866$, $p < 0.001$); therefore, for clarity, only the data for the right eyes are presented.

According to our classification of optic disc size, there were 27 (14.7%) small, 141 (76.6%) medium, and 16 (8.7%) large optic discs in this sample. The mean cupping was 0.198 (standard error ± 0.21 ; range, 0.0-0.8). The small optic discs were rarely cupped, and the large optic discs were always cupped. The relative frequency of cupping for each optic disc size is given in Table 1. It can be seen that 39.1% of all discs had no cupping, and that all small discs had no cupping. The cupping of the large discs was distributed in evenly through the whole range from 0.1 to 0.8.

It is well-known that the degree of optic disc cupping increases with ageing, as a result of non-pathological loss of fibers in older individuals. When the sample was divided into "younger" and "older" groups, the amount of cupping was slightly greater in older subjects (0.22 vs. 0.18), but this small difference was not significant ($p = 0.20$).

Discussion

One of the methods for the early detection of glaucomatous optic nerve damage in ocular-hypertensive eyes, before the development of visual field loss, consists of measuring the optic cup diameter in relation to optic disc diameter⁶. There are normal eyes with rather small optic discs, and there are normal eyes with very large optic discs. The optic disc size is larger in highly myopic eyes and smaller in highly hyperopic eyes. As this study was developed to establish norms of optic disc size and cupping, a mainly emmetropic population was studied to avoid bias in this sense, and we only included eyes with unaided 20/20 vision.

Clinical evaluation of the optic nerve varies with the ability and experience of the examiner⁷. The characterization of the optic nerve –that is, determining whether it is or

is not damaged– is time-consuming, difficult, and sometimes arduous work. The horizontal diameter of the optic disk is not constant among different subjects, but rather varies widely, over a range of approximately 1:3⁸. The measurement of the optic disk can be determined using optic disk photographs, or with the help of computerized semiautomatic optic disc analyzers, using scanning laser tomography of the optic nerve head (OCT or HRT). All of these methods are useful in ophthalmological practice and have low inter-observer variability. Although the method used in the present study is advantageous, because it requires only an inexpensive and portable instrument owned by every ophthalmologist, it is especially prone to variability of measurement⁷. Therefore, only one examiner performed all the measurements, comparing disc diameter with the invariant diameter of the spot of light on the retina and establishing the particular cupping of each disc alternatively looking at a figure with the Armaly scale (Fig. 2). Disk diameter can also be measured ophthalmoscopically, using a standard Goldmann three-mirror contact lens and a commercial slit lamp with adjustable beam length; but the instrument used in this study fits in a pocket, and it was the only one available in the examiner's office for this study involving outpatients coming for a general health checkup.

The diameter of the optic cup also varies widely among individuals⁶. In normal eyes, the areas of the optic disk and optic cup are correlated with each other: the larger the optic disk, the larger the optic cup⁹. Care must be taken in glaucoma diagnosis, to take into account that small optic discs normally have no optic cup and that visual field loss may occur before cupping appears. The opposite is true for larger discs, in which cupping is frequently non-pathological, without damage due to glaucoma neither in the disc nor in the visual field. In many cases, disc hemorrhages, parapapillary chorioretinal atrophy and the study of the retinal nerve fiber layer, either by direct biomicroscopy or by OCT may give insight as to whether a greater than normal optic cupping indicates optic nerve damage in larger cupped discs⁶.

Recent studies have shown that the thickness of the retinal optic fiber layer decreases, not only with glaucoma, but also with normal ageing^{10,11}. This decrease has been shown to be on the order of 1.6 microns or 2.4 microns for a period of 10 years in those cross-sectional studies with OCT measurement of the retinal nerve fiber layer thickness^{10,11}. As this nerve fiber layer has a thickness of about 90-100 microns, this age-related decrease represents a change of 2% in thickness in ten years. This small amount may make the cupping appear more pronounced with ageing, as we found in this study, although the small difference between young and older subjects was not significant.

In the present study, there was a high prevalence of men (81%). This relative high prevalence of men is common in studies involving office-workers of primarily managerial and executive level professionals¹. As there

TABLE 3.– Cup-to-disc ratio in different studies

	Age (years)	Cup-to-disc ratio
Present Study	21-75	0.20
Rotterdam Study 12	55+	0.30
Singapore Malay Study13	40-80	0.39
Blue Mountains Eye Study14	49+	0.43
Baltimore Study (Blacks)15	40+	0.56
Baltimore Study (Whites)15	40+	0.49
Vellore Eye Study16	–	0.56
Wisconsin Study17 (Diabetics)	30+	0.44

were no differences in disc size or cupping among sexes (data not shown), the relative high prevalence of men in the sample should not bias our results.

The results of this study can be compared to those obtained by ophthalmoscopic examination of the optic nerve head in the Rotterdam Study¹². That study reported a mean cup-to-disc ratio of 0.3, which is not very different from approximately 0.2 found in the present study; and a cup-to-disc ratio of 0.7 was found to be definitely abnormal, in both studies (Table 1 in the present study). The age of the Rotterdam population was ≥ 55 years, older than in the present sample, so the greater cupping reported in the Rotterdam study might be due to an age-related loss of optic fibers. Table 3 compares the mean cup-to-disc ratio of this study with the Singapore Malay Study¹³, Blue Mountains Eye Study¹⁴, Baltimore Study¹⁵, Vellore Eye Study¹⁶ and Wisconsin study¹⁷. The values in other studies were higher than the present ones, perhaps because the planimetric methods used commonly in population-based studies tend to give higher values than the ophthalmoscopic method of quantifying optic disc-cupping (i.e., with the ophthalmoscopic method, shallow cuppings are under-reported)¹².

The aim of this study was to show how frequently these “small” or “large” optic discs are likely to be encountered

TABLE 1.– Percentage (%) of subjects with each disc cupping according to disc size

Armaly Cupping Scale	Total n=184	Disc Size		
		Small n=27	Medium n=141	Large n=16
0.0	39.1	14.1	25.0	–
0.1	10.3	0.5	8.7	1.1
0.2	15.2	–	15.2	–
0.3	10.9	–	9.8	1.1
0.4	9.8	–	6.0	3.8
0.5	6.0	–	6.0	–
0.6	5.4	–	4.3	1.1
0.7	2.7	–	1.6	1.1
0.8	0.5	–	–	0.5
0.9	–	–	–	–

TABLE 2.– Percentage (%) of subjects with each disc cupping

Armaly Cupping Scale	% Present study n=184	% Armaly study n=862
0.0-0.1	49.4	19.1
0.2-0.3	26.1	28.2
0.4-0.5	15.8	31.1
0.6-0.7	8.1	16.2
0.8-0.9	0.5	5.3

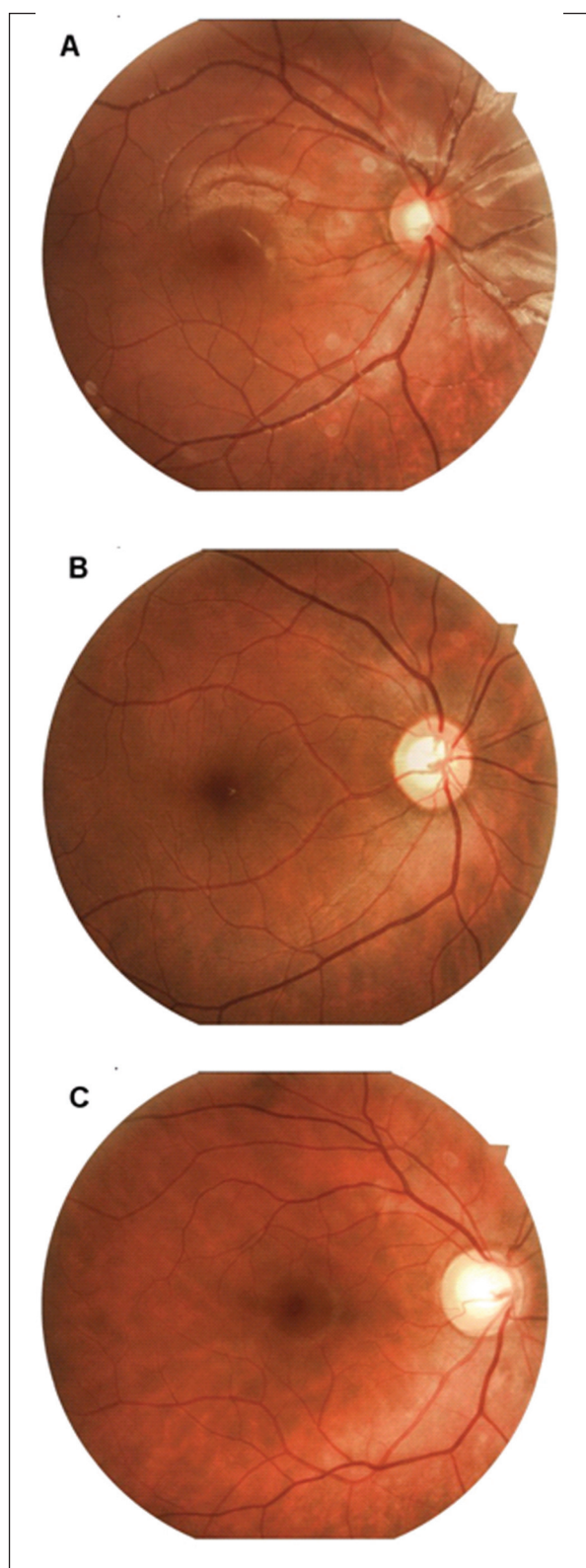


Fig. 3.– Small (A), medium (B) and large (C) discs with 0.6 cupping.

in the clinic, in eyes without glaucoma. According to Table 1, almost 40% of the discs were free of any cupping and cupping of 0.6 or more was present in only 8% of this non-glaucomatous, emmetropic population. Only 16/184 subjects had large discs; about half of these had optic discs with 0.4 cupping, and cupping of 0.8 was seen in only one subject. These data show that cupping of 0.7 or more is relatively infrequent in an unselected population, and suggest that these are the ones that should be studied to discard glaucoma. For reference, in Table 2, the results of this study are compared to those originally presented by Armaly in 1969. It can be seen that we found a higher prevalence of "small" cupping, perhaps because ours was an unselected sample of healthy office-workers and not an outpatient sample being examined for some ocular complaint.

The simple method of examining the optic disc, described in the present paper, is appropriate for initial screening in clinical practice and is suitable for use by ophthalmologists or other clinicians with experience in direct ophthalmoscopy. The direct ophthalmoscope is a small, easy to use, battery-loaded instrument. With only moments of our time, it can yield countless clues to optic nerve status in an appropriate diagnostic way. Figs 3 (A, B and C) are fundus photos of three non-glaucomatous optic discs of small, medium and large sizes, each with a 0.6 cupping, showing which are biggest cuppings that could be considered normal in a clinical examination. Greater cupping should be considered abnormal and referred for study by a specialist.

Acknowledgments: The costs of publication of this paper have been supported by the Faculty of Medicine at the University Institute of Health Sciences of the Hector Alejandro Barceló Foundation, Argentina (www.barcelo.edu.ar).

Conflict of interest: None to declare

References

1. Cortinez MF, Chiappe JP, Iribarren R. Prevalence of refractive errors in a population of office-workers in Buenos Aires, Argentina. *Ophthalmic Epidemiol* 2008; 15: 10-6.
2. Gross PG, Drance SM. Comparison of a simple ophthalmoscopic and planimetric measurement of glaucomatous neuroretinal rim areas. *J Glaucoma* 1995; 4:314-6.
3. Armaly MF. Genetic Determination of cup/disc ratio of the optic nerve. *Arch Ophthalmol* 1967; 78: 35-43.
4. Armaly MF. The optic cup in the normal eye: Cup width, depth, vessel displacement, ocular tension and outflow facility. *Amer J Ophthalmol* 1969; 68: 401.
5. Armaly MF, Sayehg RE. The cup-disc ratio. The findings of tonometry and tonography in the normal eye. *Arch Ophthalmol* 1969; 82: 191-6.
6. Jonas JB, Budde WM, Panda-Jonas S. Ophthalmoscopic evaluation of the optic nerve head. *Surv Ophthalmol* 1999; 43: 293-320.
7. Lichter PR. Variability of expert observers in evaluating the optic disc. *Trans Am Ophthalmol Soc* 1976; 74: 532-72.
8. Jonas JB, Gusek GC, Naumann GO. Optic disc, cup and neuroretinal rim size, configuration and correlations in normal eyes. *Invest Ophthalmol Vis Sci* 1988; 29: 1151-8.
9. Bengtsson B. The variation and covariation of cup and disk diameters. *Acta Ophthalmol* 1976; 54: 804-18.
10. Parikh RS, Parikh SR, Sekhar GC, et al. Normal age-related decay of retinal nerve fiber layer thickness. *Ophthalmology* 2007; 114: 921-6.
11. Feuer WJ, Budenz DL, Anderson DR, et al. Topographic differences in the age-related changes in the retinal nerve fiber layer of normal eyes measured by Stratus optical coherence tomography. *J Glaucoma* 2011; 20: 133-8.
12. Wolfs RC, Ramrattan RS, Hofman A, de Jong PT. Cup-to-disc ratio: ophthalmoscopy versus automated measurement in a general population: The Rotterdam Study. *Ophthalmology* 1999; 106: 1597-601.
13. Amerasinghe N, Wong TY, Wong WL, et al. SiMES Study Group. Determinants of the optic cup to disc ratio in an Asian population: the Singapore Malay Eye Study (SiMES). *Arch Ophthalmol* 2008; 126: 1101-8.
14. Healey PR, Mitchell P, Smith W, Wang JJ. Relationship between cup-disc ratio and optic disc diameter: the Blue Mountains Eye Study. *Aust N Z J Ophthalmol* 1997; 25 Suppl 1: S99-101.
15. Varma R, Tielsch JM, Quigley HA, et al. Race-, age-, gender-, and refractive error related differences in the normal disc. *Arch Ophthalmol* 1994; 112: 1068-78.
16. Jonas JB, Thomas R, George R, et al. Optic disc morphology in South India: the Vellore Eye Study. *Br J Ophthalmol* 2003; 87: 189-96.
17. Klein BEK, Moss SE, Magli YL, et al. Optic disc cupping: prevalence findings from the WESDR. *Invest Ophthalmol Vis Sci* 1989; 30: 304-9.